


PATIENT

K-Sea Watkins

PRESENTING CLINICAL SIGNS

History: Not doing well. Has been on Vetmedin for a while. Decreased appetite, labored breathing. Concurrent pancreatitis (based on bloodwork) and possible Cushings (high ALP).
 -Abnormal PE/Chem/CBC/UA Results: Increased Retics, mildly increased Glucose, increased SDMA, Increased K+, decreased NA:K ratio, increased ALP(1394), increased Cholesterol, Lipase and SPCL(647).

SPECIES

Canine

ECHOCARDIOGRAM FINDINGS

2D, m-mode and doppler imaging is available. Mild thickening of mitral valve leaflets with no obvious prolapse into the left atrial lumen. Trace mitral regurgitation with a normal left atrial dimension. Normal LV diameter with adequate myocardial function. LV wall dimension is normal. The tricuspid valve appears mildly thickened with mild tricuspid regurgitation. Mild to moderate right atrial enlargement, moderate right ventricular hypertrophy with mild dilation consistent with pulmonary arterial hypertension. Septal flattening in systole. TR velocity consistent with a PG of 60mmHg (normal <25), which is thought to be an underestimation. The pulmonic and aortic valves are normal in morphology and mobility. Mild main PA and branch dilation. Trace pulmonic insufficiency. Normal pulmonic and aortic outflow velocities. No pericardial or pleural effusion noted. No cardiac tumors observed.

BREED

White Highland Terrier

SEX

Male Neutered

AGE

11 years

WEIGHT

24.2lbs

CARDIAC CHART
INTERPRETED BY

 Maggie Machen Lamy,
 DVM DACVIM
 (Cardiology)

CANINE CARDIAC PARAMETERS	MR VMAX (m/s)	TR VMAX (m/s)	LA/AO (Boon method)	LA/AO (Heart Base; Swe)	FS (%)	EF (%)	EPSS (cm)
NORMAL PARAMETER	4.5-5.5	<2.7	1.3	<1.6	28-40	40-100	<0.6
PATIENT	4.5	3.6	1.2	1.2	50	92	NM
CANINE CARDIAC PARAMETERS	HR (BPM)	AV VMAX (m/s)	PV MAX (m/s)	BODY WEIGHT (kg)	LA 2D short axis Base view (cm)	LVIDd Avg; 2D and m-mode short axis (cm)	LVIDs Avg; 2D and m-mode short axis (cm)
NORMAL PARAMETER	50-100	0.7-1.7	0.7-1.6	BELOW	BELOW	BELOW	BELOW
PATIENT	83	0.9	1.3	11.0	1.8	1.8	0.9
*Normal chamber parameters expressed as a mean value (SD)				3	1.27 (5.3)	2.46 (2.46)	1.36 (5.5)
BODY WEIGHT DEPENDENT PARAMETERS				5	1.40 (4.5)	2.74 (5.2)	1.60 (4.7)
*Note: All measurements based upon multi-modal images and methods. An average value is reported.				10	1.50 (3.8)	3.27 (3.5)	2.06 (3.1)
				15	1.83 (2.0)	3.71 (2.4)	2.43 (2.1)
				20	2.02 (1.9)	4.14 (2.2)	2.80 (2.0)
				25	2.18 (2.4)	4.48 (2.9)	3.10 (2.5)
				30	2.33 (3.3)	4.83 (3.9)	3.39 (3.4)
				35	2.48 (4.3)	5.17 (5.0)	3.69 (4.5)
				40	2.62 (5.2)	5.48 (6.1)	3.96 (5.4)
				50	2.88 (7.1)	6.07 (8.3)	4.46 (7.4)

INVOICE

21635

DATE

10/20/21

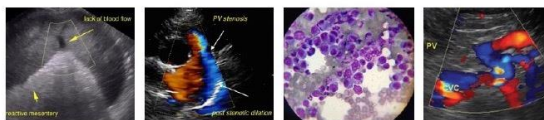
HOSPITAL NAME

 Beamsville Animal
 Hospital

REFERRING VET

Dr. Adele

Adapted from June Boon, Veterinary Echocardiography, 1998
 Rishniw M and Hollis NE, J Vet Intern Med 2000; 14:429-435
 Hansson et al, Vet Rad and Ultrasound 2002
 Bonagura et al. Echocardiography: principles of interpretation, Vet Clin North Am 15:1177, 1995



PATIENT

K-Sea Watkins

SPECIES

Canine

BREED

White Highland Terrier

SEX

Male Neutered

AGE

11 years

WEIGHT

24.2lbs

INTERPRETED BY

Maggie Machen Lamy,
DVM DACVIM
(Cardiology)

IMAGING PERFORMED BY

Kelly Reschny, RVT

HOSPITAL NAME

Beamsville Animal
Hospital

REFERRING VET

Dr. Adele

INVOICE

21635

DATE

10/20/21

INTERPRETATION OF THE FINDINGS & FURTHER RECOMMENDATIONS

Pulmonary hypertension (PAH) is present, as evidenced by a hypertrophied right heart, dilated MPA and elevated TR velocity. The estimated systolic pulmonary arterial pressure is >60mmHg, with normal being <25mmHg. This is causing pressure overload of the right ventricle. The left heart is essentially normal with a small mitral leak, indicating low risk for complication such as left-sided CHF. No additional issues are identified.

Clinical signs of weakness, heavy breathing, cyanosis, and syncope are attributed to severe PAH. The underlying genesis of PAH is poorly understood in cases other than heartworm infestation, though it occurs with increased frequency in a variety of forms of chronic lung disease and in patients with idiopathic pulmonary fibrosis. If not performed, a heartworm antigen test is recommended. Given the chronicity of the disease seen here, COPD/chronic bronchitis and/or primary PF as an underlying cause with an acute secondary exacerbating insult (infectious or inflammatory) is suspected. This signalment is highly predisposed to Idiopathic Pulmonary Fibrosis, and **baseline chest radiographs are strongly recommended**. The pulmonary pattern should be assessed, and perhaps additional therapy such as anti-inflammatory steroids, etc. may be indicated. Patients with this degree of PAH and pulmonary disease can develop right-sided congestive heart failure (ascites), debilitating cyanosis, labored breathing and exertional syncope if poorly controlled.

Given the reported respiratory signs, the most common cause is an infectious or inflammatory insult causing a decline in already poor oxygenation status. A PTE cannot be ruled out. Coverage with broad spectrum pulmonary antibiotic (fluoroquinolone) is recommended, pending CXR results. In addition to vasodilation using pimobendan and sildenafil. Lasix is contraindicated, as diuretics can actually further reduce preload in cases of debilitating PAH and worsen clinical signs. Depending on patient stability, hospitalization for oxygen support, IV antibiotics and supportive care may be necessary.

Once stable, use of theophylline and/or taper course of anti-inflammatory steroids can also be beneficial in these cases, to treat exertional dyspnea or acute flare ups and decrease the inflammatory component as much as possible. PRN use of cough suppressants may also be beneficial. Unfortunately, the prognosis overall is poor, however I am hopeful we can provide some medical relief going forward.

Omega fatty acid supplementation (anti-inflammatory) may be of some long-term benefit. Monitor for worsening of labored breathing, exercise intolerance or collapse episodes.

PLAN

Baseline CXR is strongly recommended. Consider a course of pulmonary antibiotics (Enrofloxacin or similar) IV or PO depending on patient stability. Institute sildenafil (Viagra) 1-2mg/kg PO q8h. Institute Pimobendan 0.2-0.3mg/kg PO q12h. Can also use hydrocodone, taper course of steroids, and/or theophylline depending on chronic clinical signs of cough/exertional dyspnea.

Recommend recheck echocardiogram in 6 months to reassess pulmonary pressures, sooner if any development of clinical signs.



PATIENT

K-Sea Watkins

SPECIES

Canine

BREED

White Highland Terrier

SEX

Male Neutered

AGE

11 years

WEIGHT

24.2lbs

INTERPRETED BY

Maggie Machen Lamy,
DVM DACVIM
(Cardiology)

**IMAGING
PERFORMED BY**

Kelly Reschny, RVT

HOSPITAL NAME

Beamsville Animal
Hospital

REFERRING VET

Dr. Adele

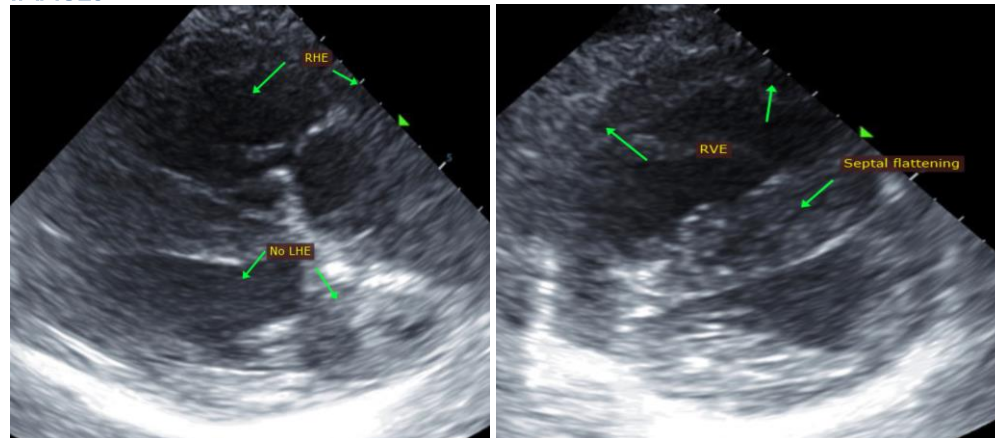
INVOICE

21635

DATE

10/20/21

IMAGES



The information and recommendations provided are based on the images presented by the referring veterinarian. No evaluation can be communicated regarding pathology that was not visible in the image/video clips provided.

Thank you for this referral. This report was generated using transcription software, and minor dictation errors may be present. If the clinical or image interpretation does not parallel your findings or if I can be of any further assistance, please contact me.

Maggie Machen Lamy, DVM

Diplomate of the American College of Veterinary Internal Medicine (Cardiology)

info@sonopath.com